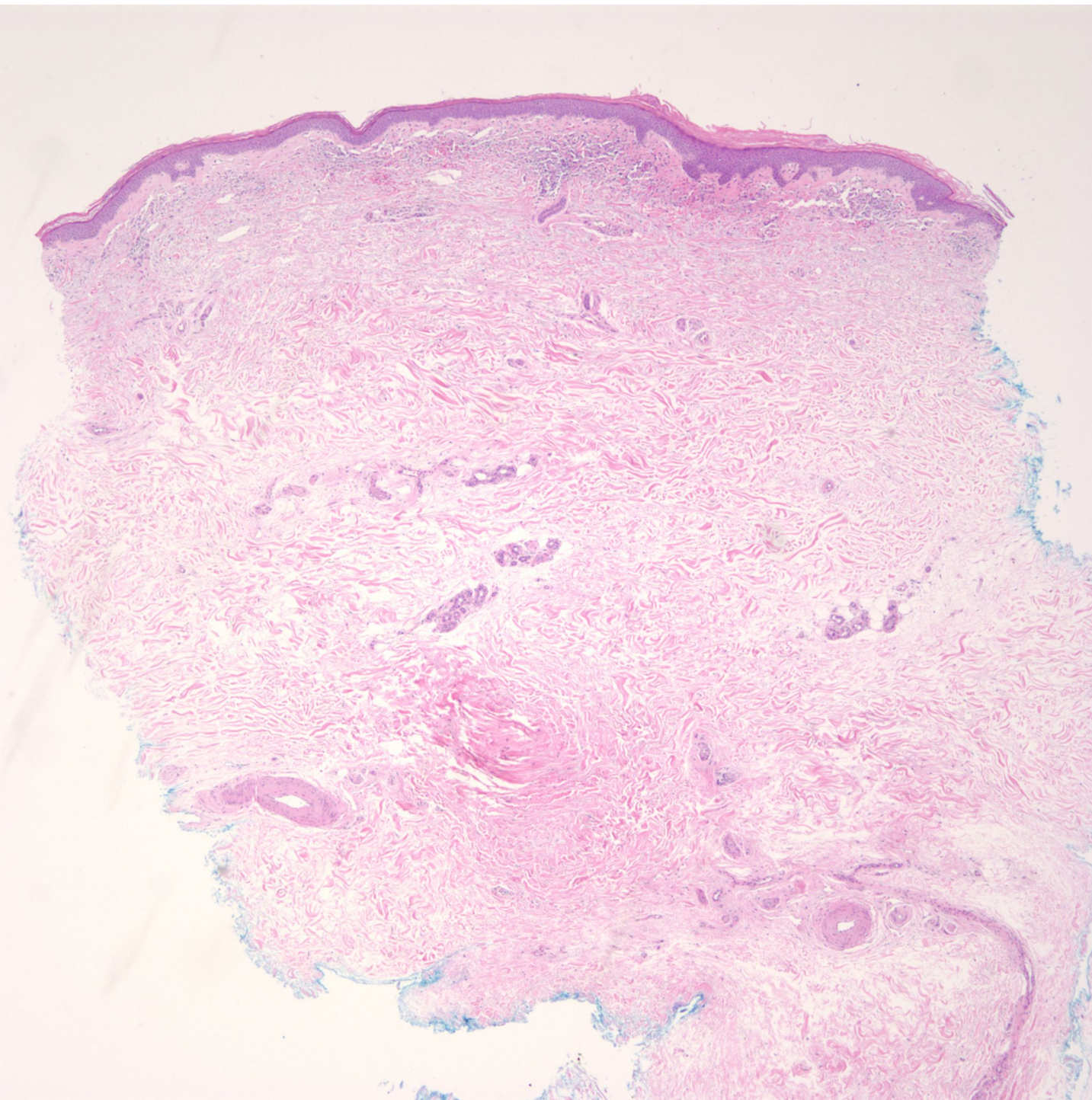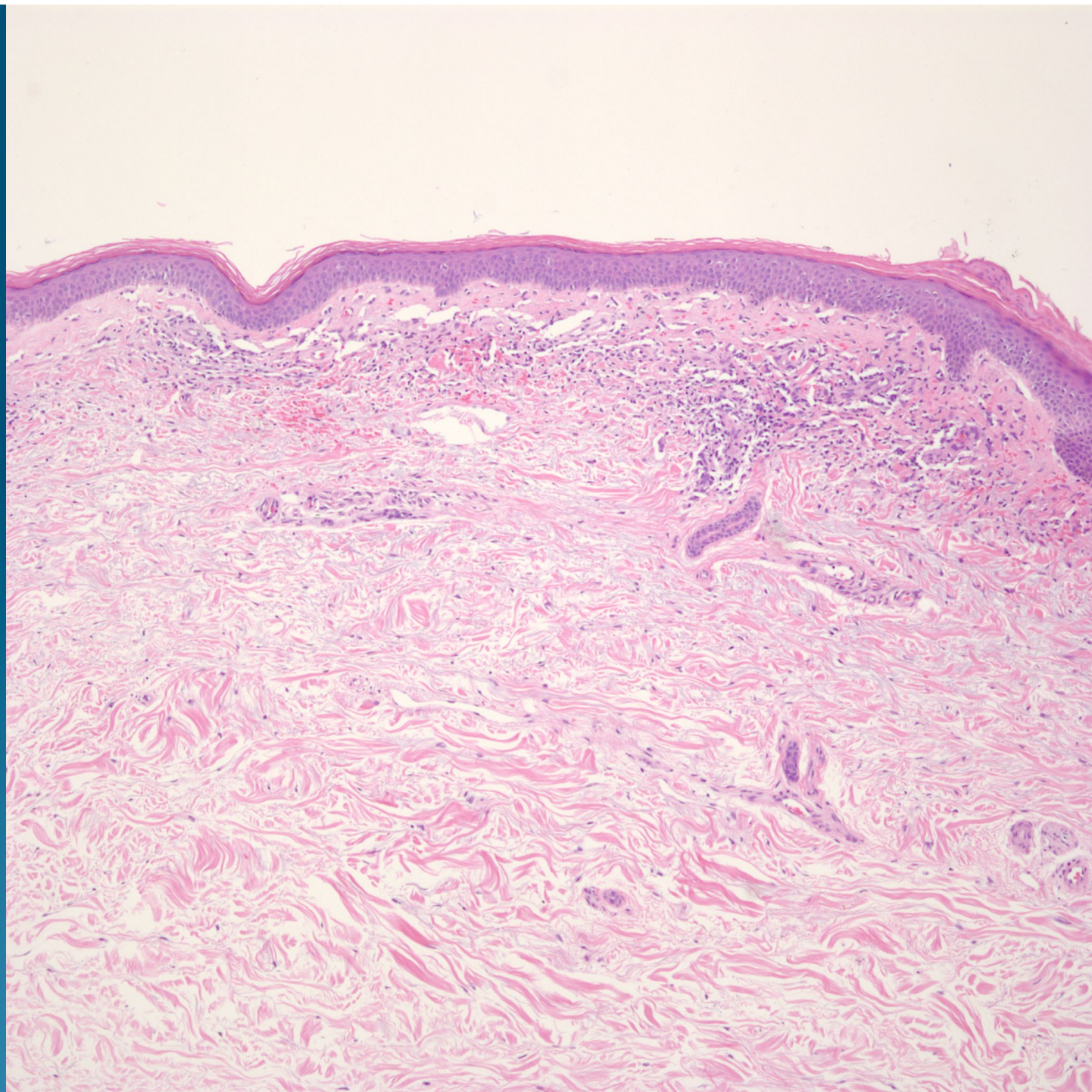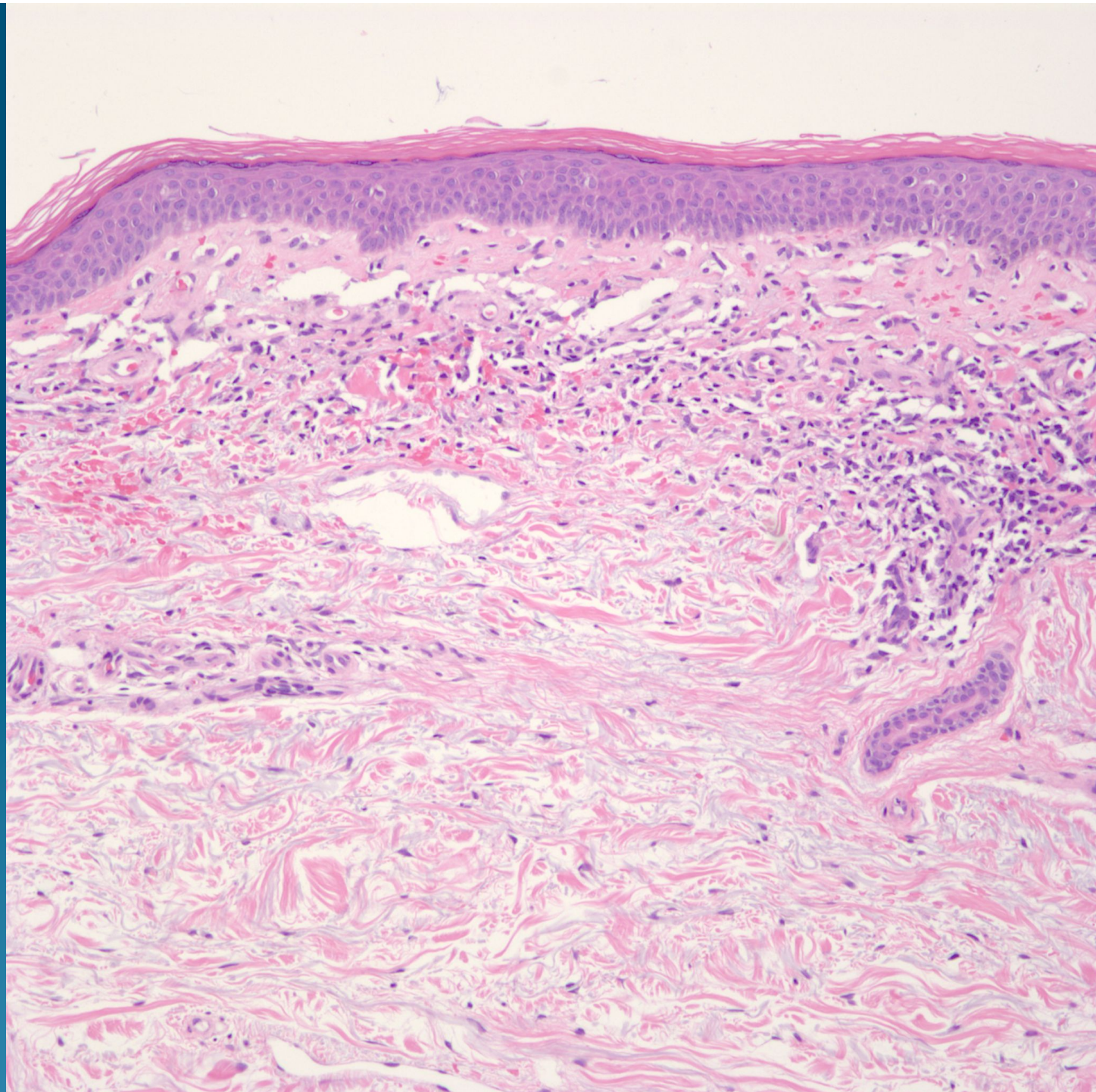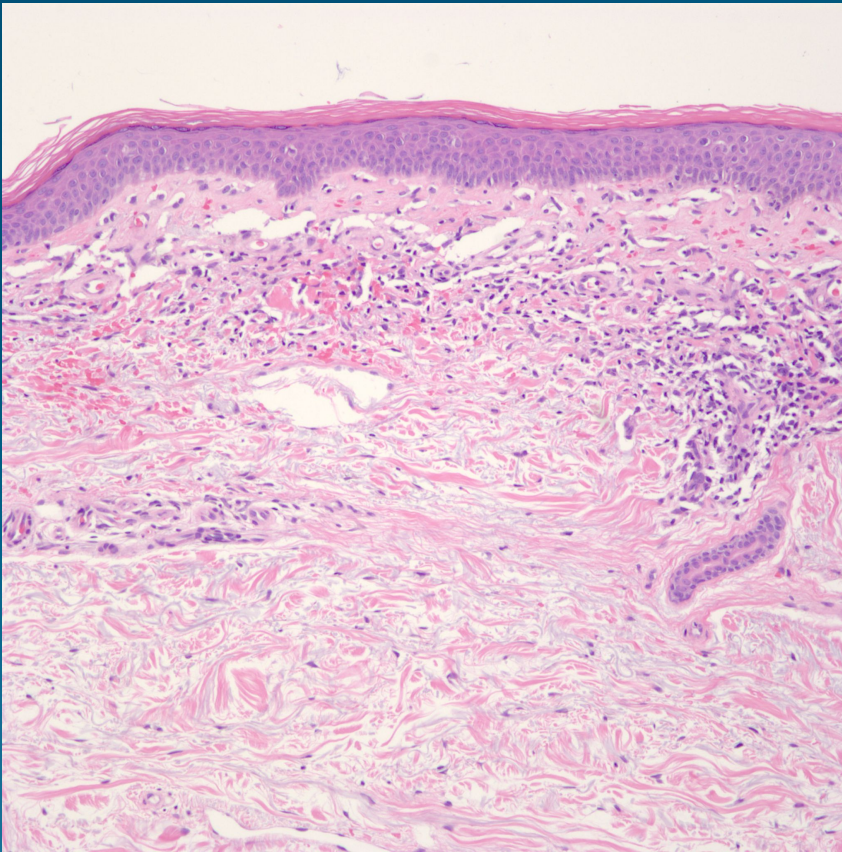


Changes consistent with Pigmented Purpuric Dermatosi

Pearls



- Superficial perivascular and interstitial dermatitis with extravasated rbc's
- No cytologic atypia of inflammatory cells
- No vasculitis or interface dermatitis
- Beware cases of MF arising in this clinical and histopathological setting